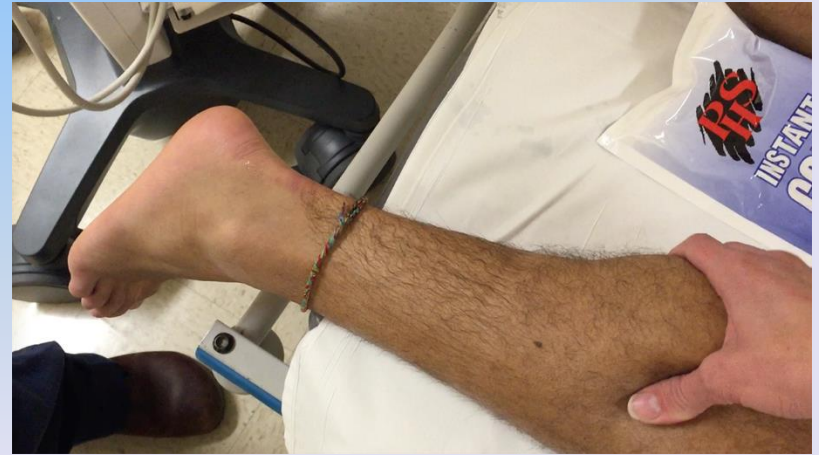
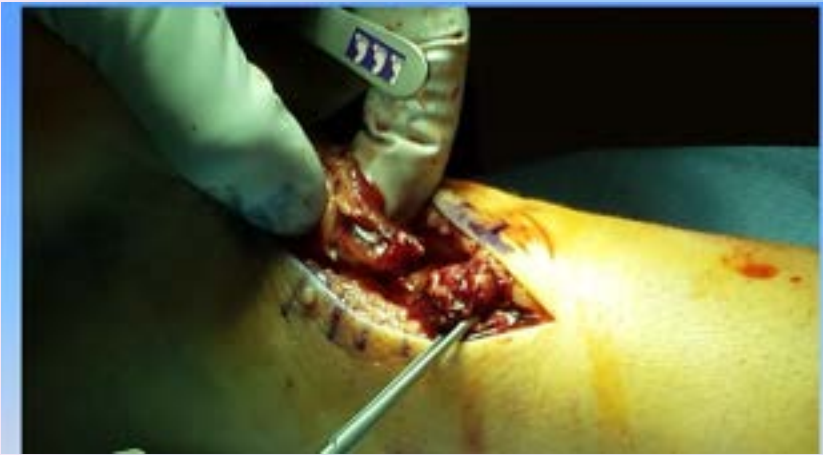
Achilles Tendon Ruptures: To Cut or Not to Cut

Chad Carlson, MD

2/8/25

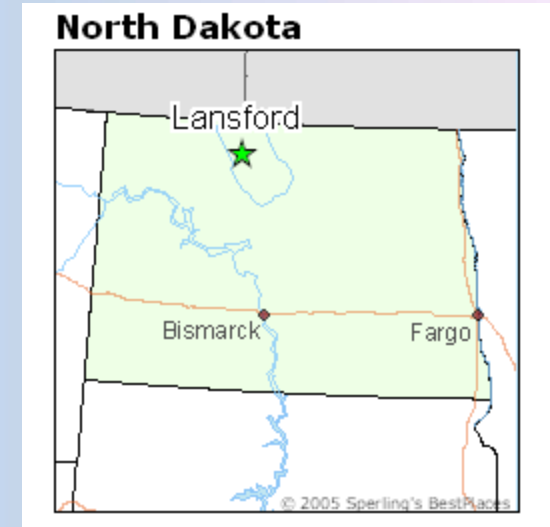

Disclosure

- No Conflicts of Interest

My Biography

- Hometown: Lansford, ND
- High School: Glenburn, ND
- Undergraduate: UND
- Medical School: UND
- Residency: Grand Rapids, MI
- Fellowship: South County Orthopedic Specialists
Laguna Woods, CA
- Practice: The Bone and Joint Center
Bismarck, ND



Achilles Tendon Ruptures

- Common Injury in athletes
- Usually occurs in watershed area of blood supply 2-5 cm from insertion on calcaneus
- Operative and Non Operative options
 - Pick your patients
 - Elderly deconditioned smoker with diabetes






- Often mechanism is from an eccentric load on tendon with muscle contraction



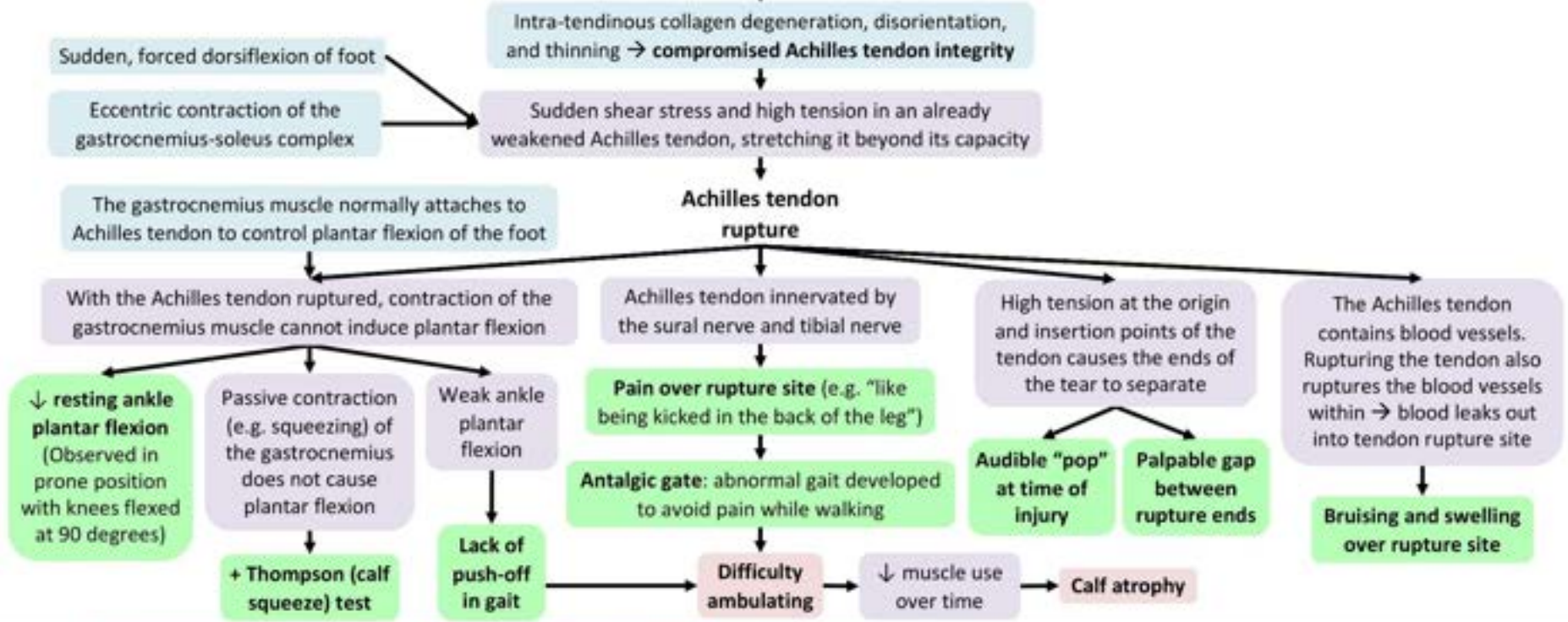
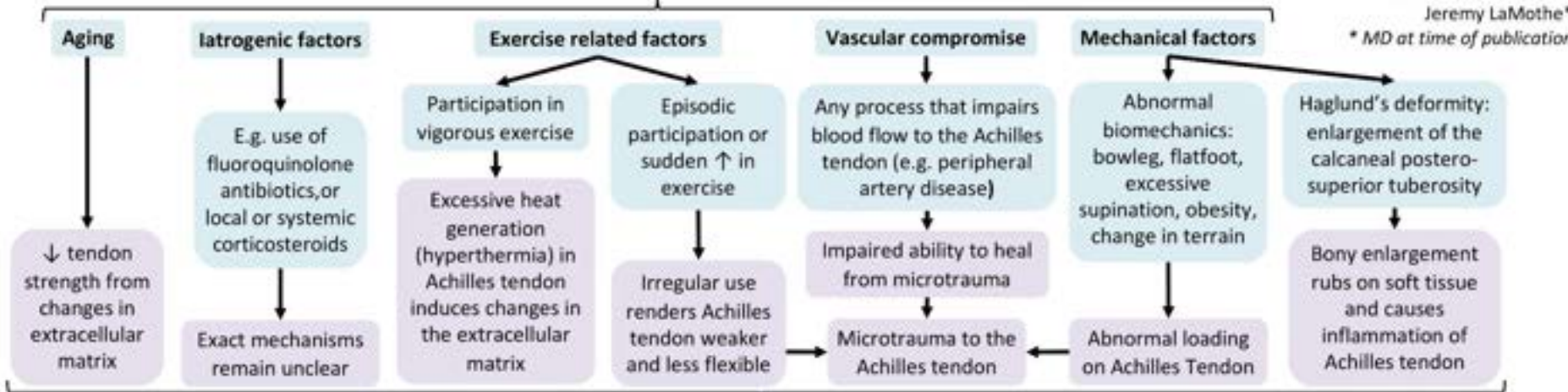
Highest Risk Activity



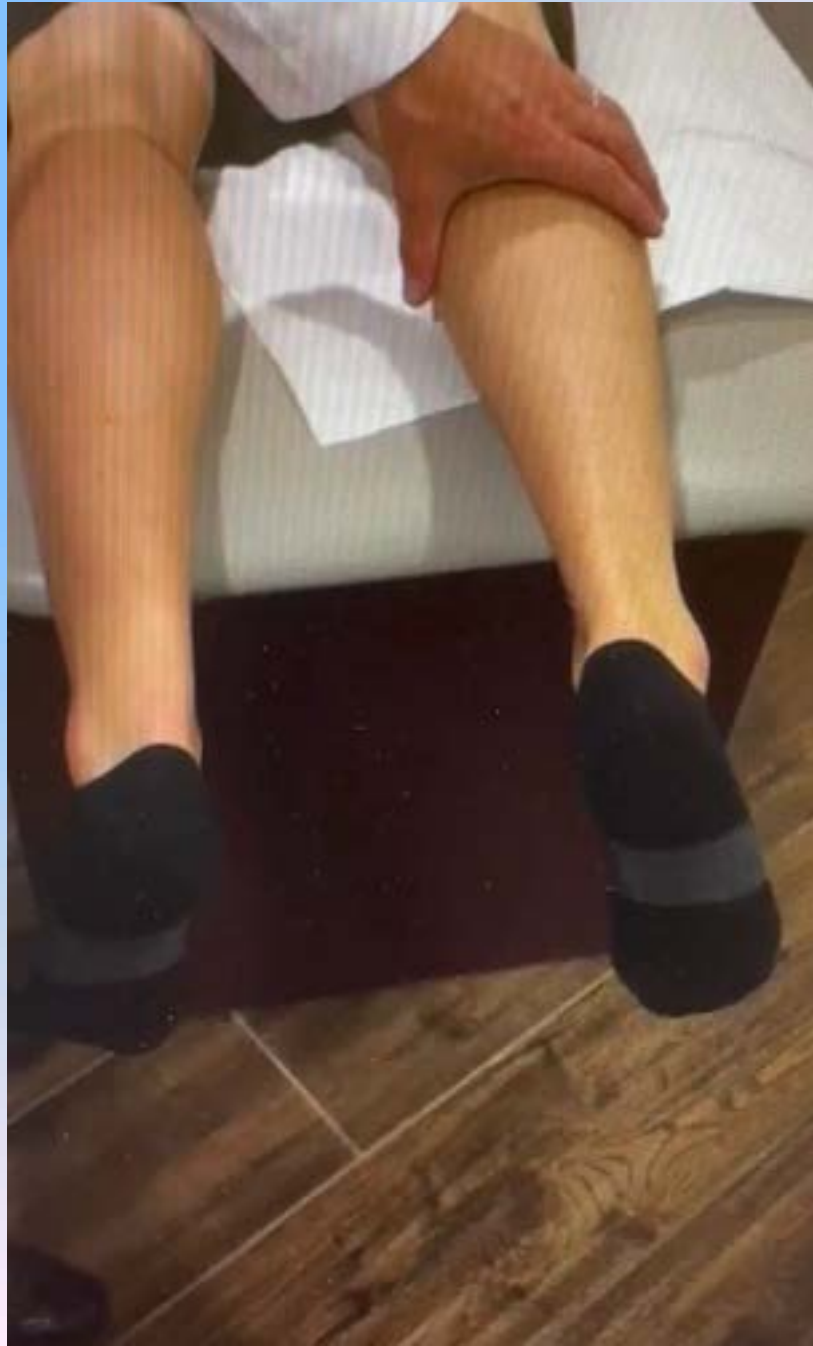Achilles Tendon Rupture: Pathogenesis and Clinical Findings

Authors: Alyssa Federico, Joseph Kendal
 Reviewers: Davis Maclean, Hannah Koury,
 Amanda Eslinger, Maninder Longowal,
 Dave Nicholl, Mehul Gupta,
 Gerhard Kiefer*, Yan Yu*,
 Jeremy LaMothe*
 * MD at time of publication

Achilles tendon ruptures are multifactorial, and may arise from any one or combination of the factors below



Thompson Test



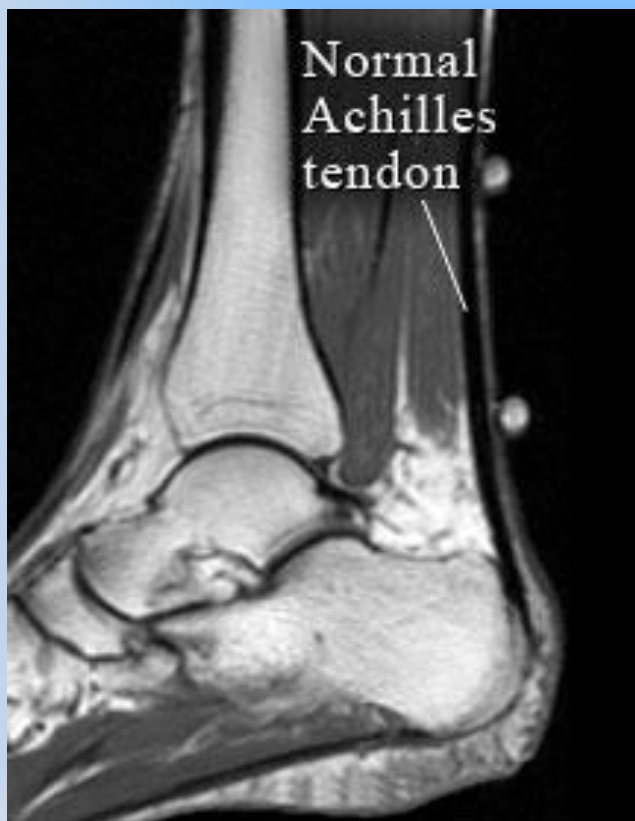


Figure 1

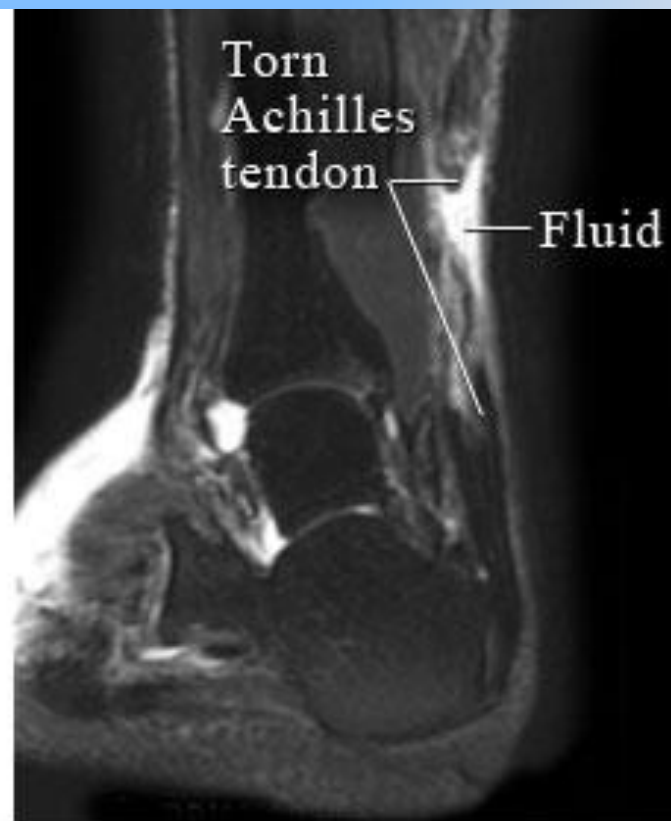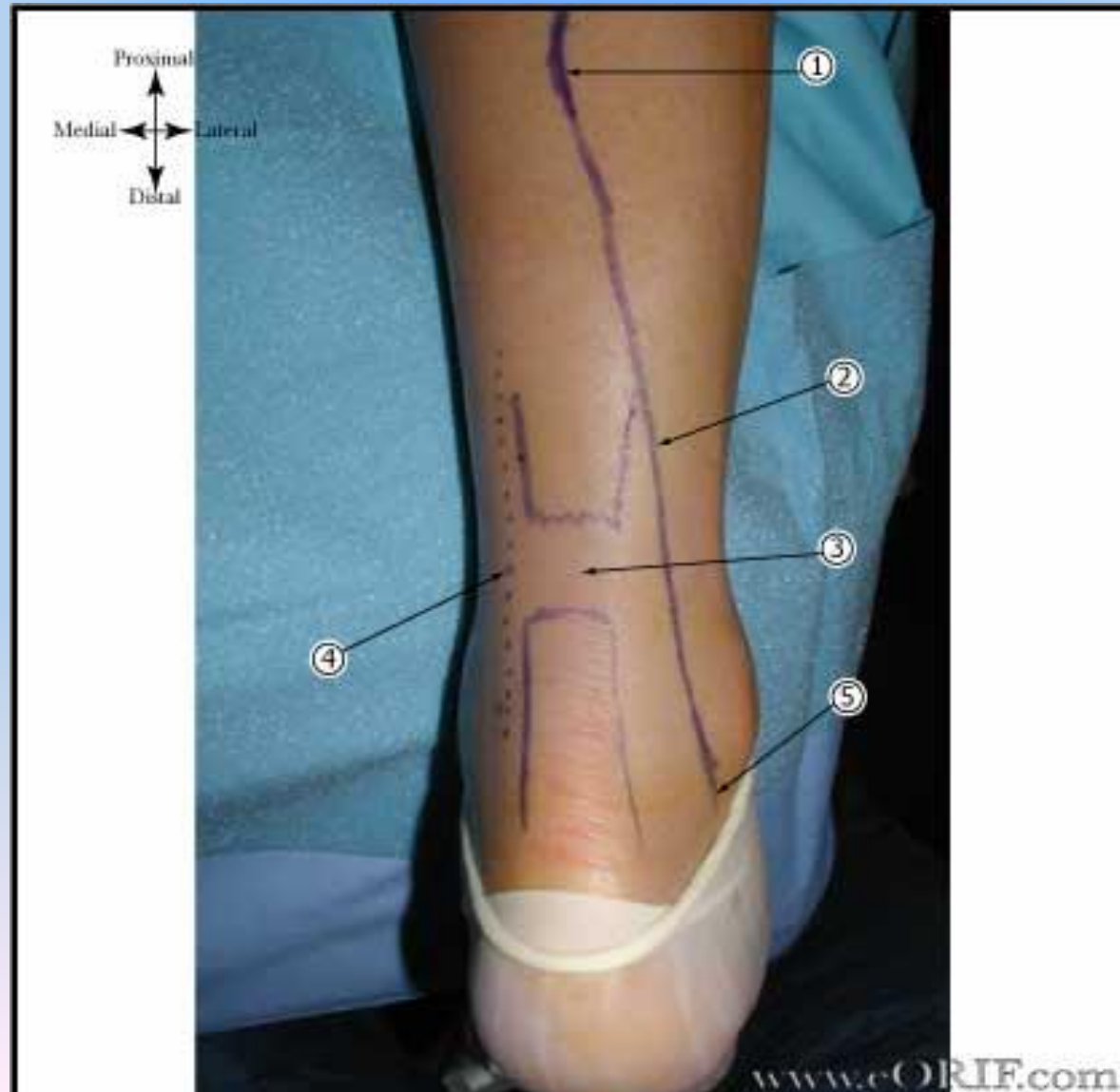


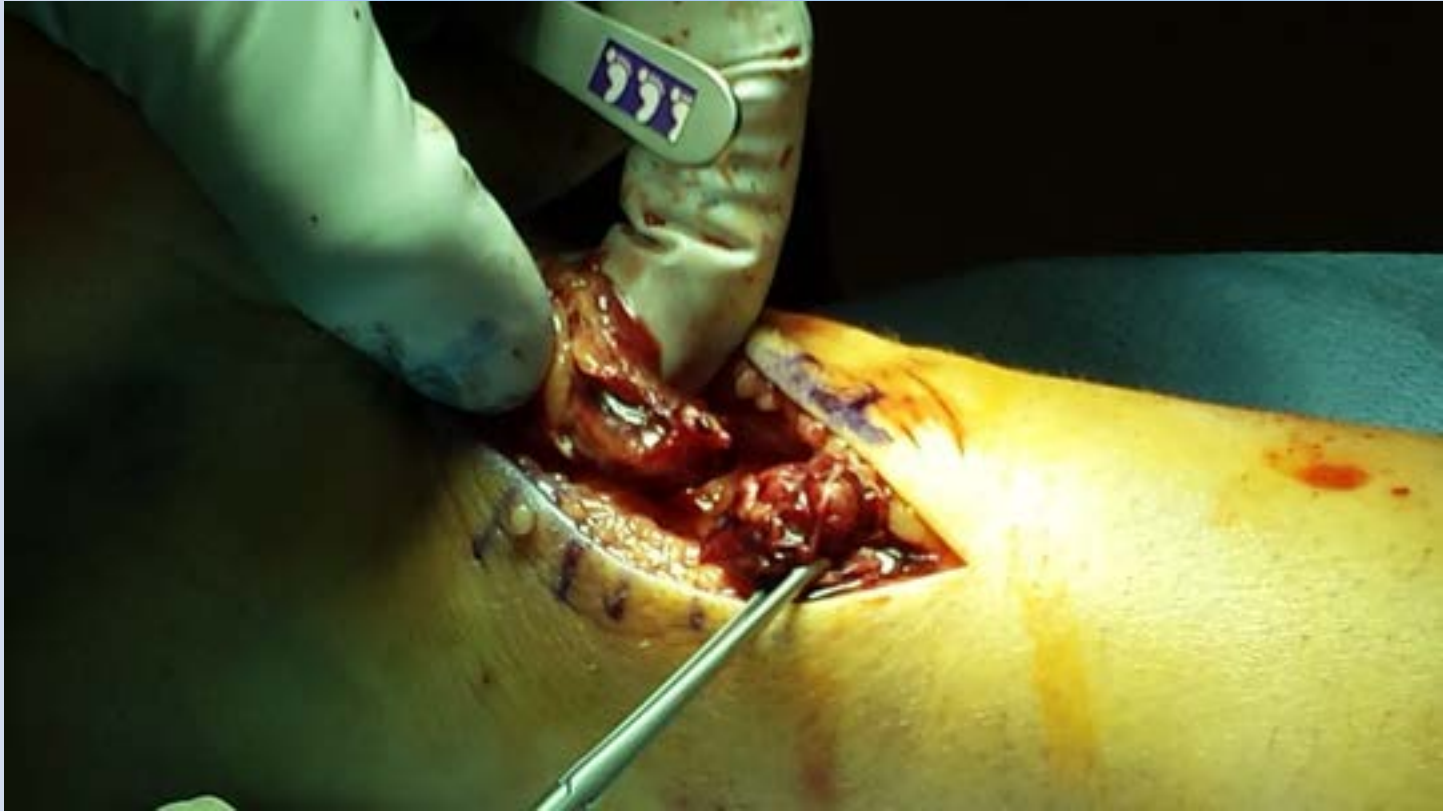Figure 2

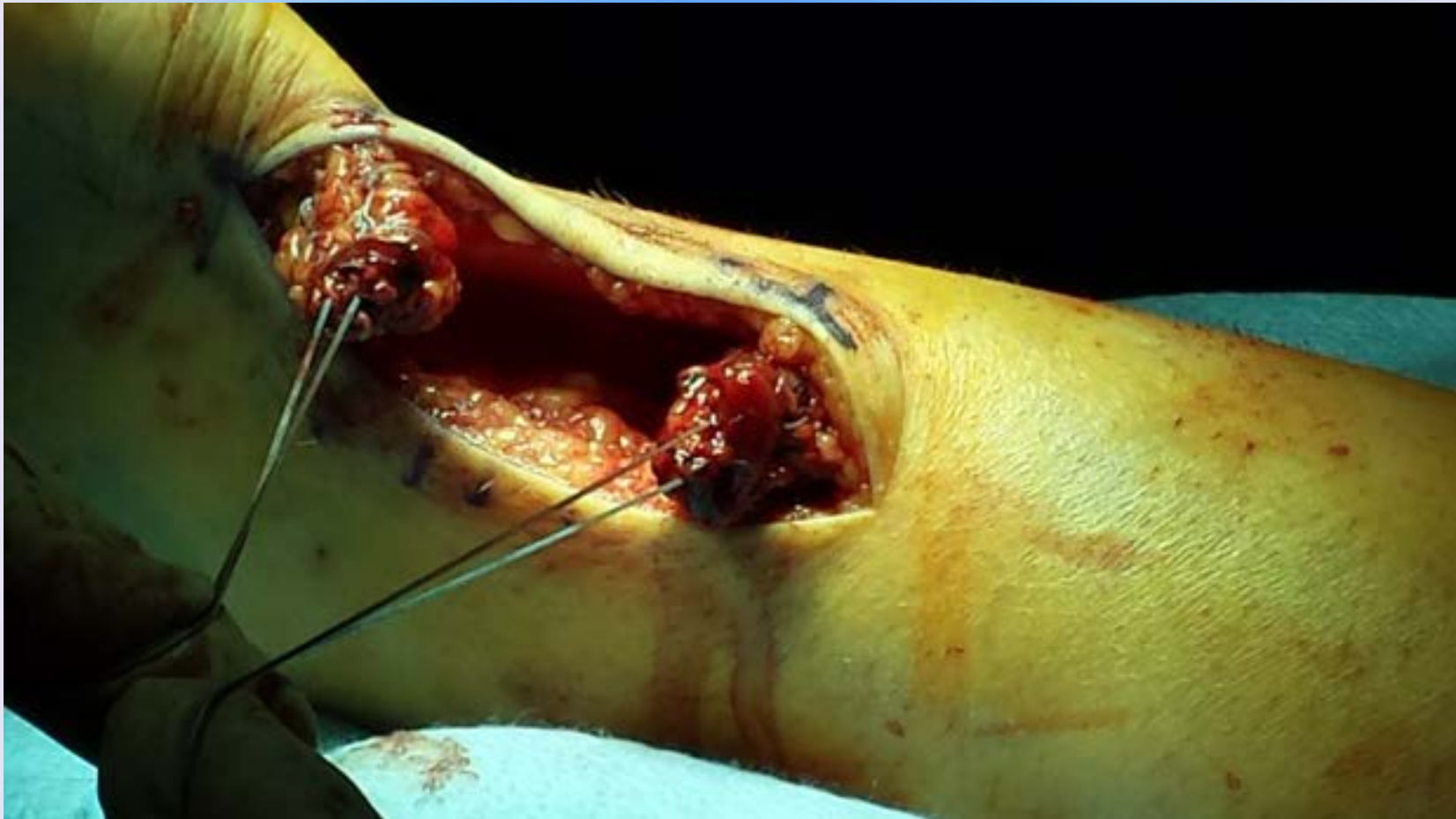Achilles Rupture = Surgery???

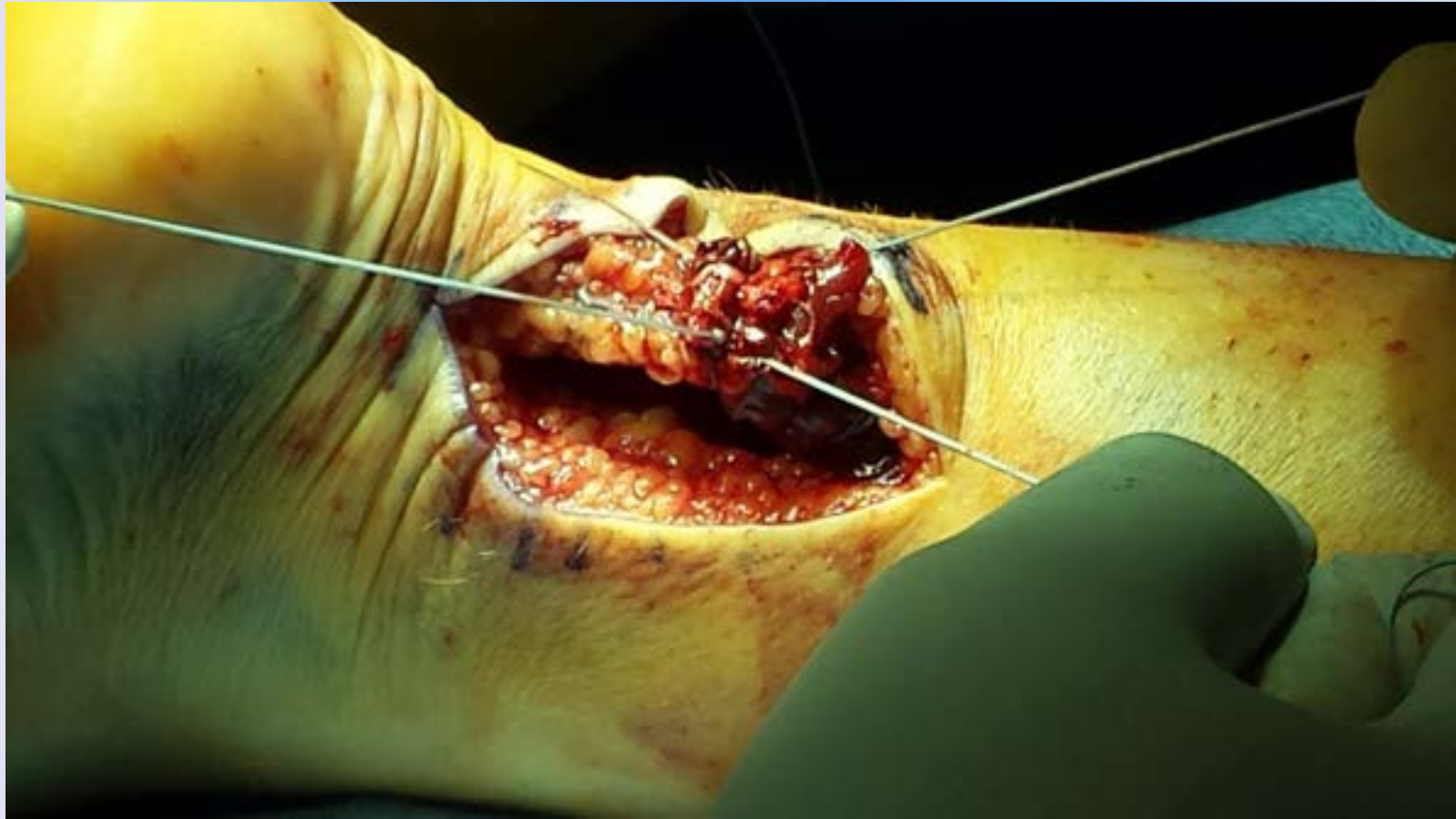- No definitive standard of care
- Highly researched with no cookbook answer on what to do
- Strength
 - Multiple studies showing surgery helps or doesn't
- Rerupture
 - Multiple studies showing decreased or equivalent
- Complications with surgery
 - Wound issues
 - Sural Nerve injury

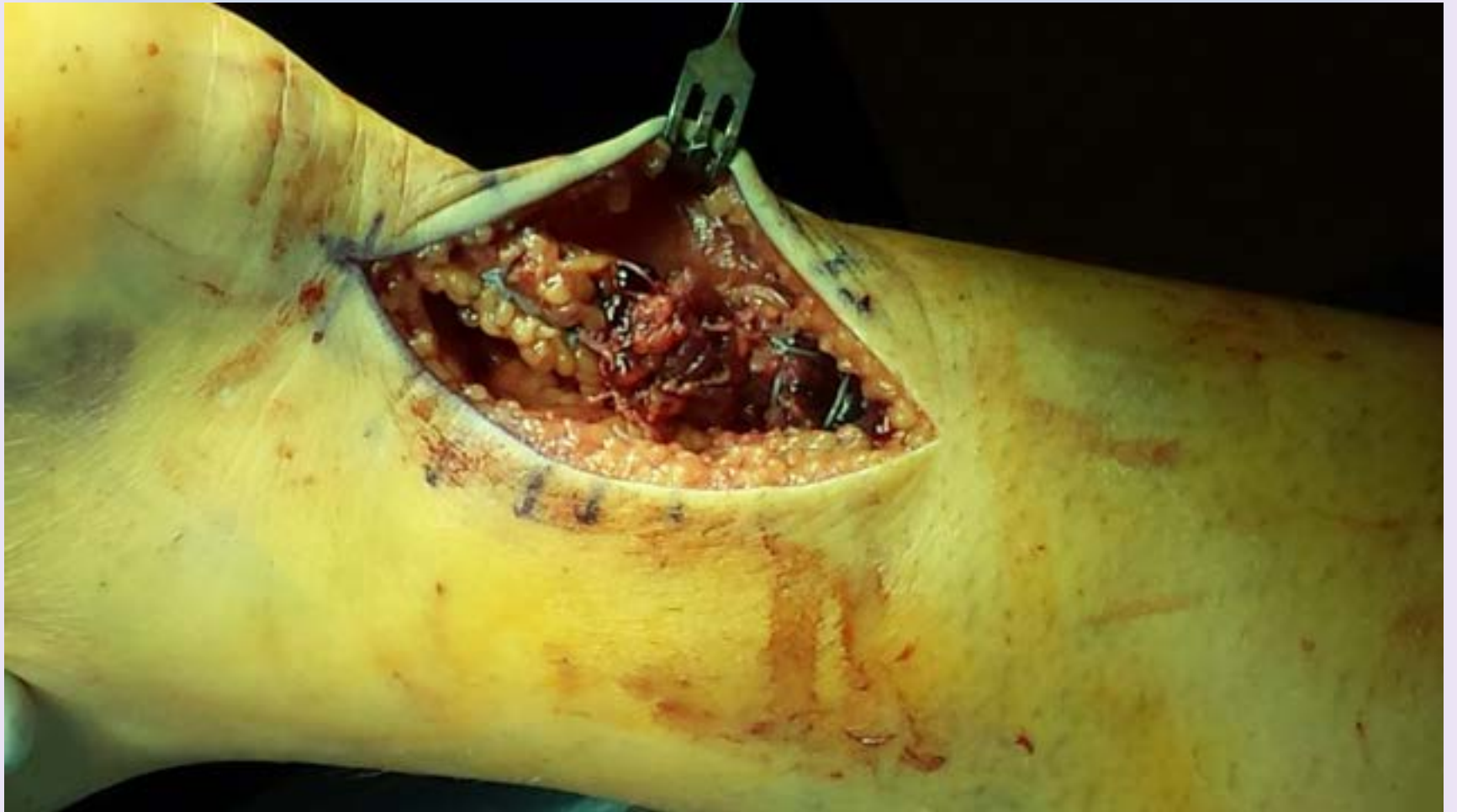Technique

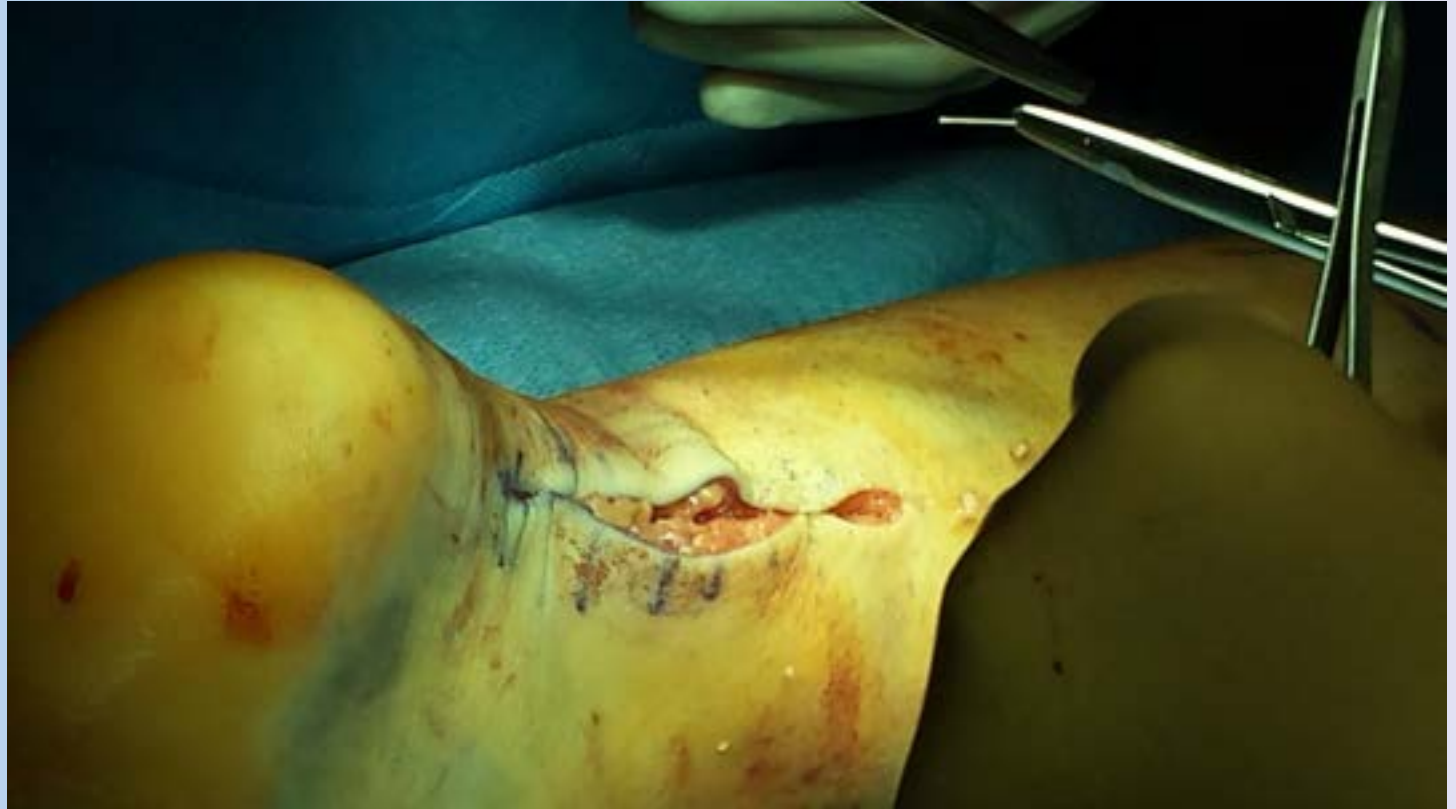











Questions

